

Evaluation of the azoospermic male: a committee opinion

Practice Committee of the American Society for Reproductive Medicine in collaboration with the Society for Male Reproduction and Urology

American Society for Reproductive Medicine, Birmingham, Alabama

The purpose of this document is to review the current methods of diagnosis and evaluation for men with azoospermia. (Fertil Steril® 2018;109:777–82. ©2018 by American Society for Reproductive Medicine.)

Earn online CME credit related to this document at www.asrm.org/elearn

Discuss: You can discuss this article with its authors and other readers at <https://www.fertstertdialog.com/users/16110-fertility-and-sterility/posts/29614-25673>

While the diagnosis of azoospermia is rare (approximately 1% of all men [1]), approximately 10%–15% of all infertile men receive this diagnosis [2]. Distinct from aspermia where no ejaculate is produced, the diagnosis of azoospermia indicates that no sperm is identified in the centrifuged pellet of two separate semen samples. The purpose of this document is to review the current methods of evaluation for azoospermic men.

THE DIAGNOSIS OF AZOOSPERMIA

Azoospermia may be classified into three categories: pre-testicular, testicular, and post-testicular diagnoses (Table 1). Pre-testicular causes of azoospermia include endocrine abnormalities having adverse effects on spermatogenesis (secondary testicular failure). Testicular causes of azoospermia (primary testicular failure) encompass disorders of spermatogenesis intrinsic to the testes. Post-testicular causes of azoospermia relate to ejaculatory dysfunction or ductal obstruction that impairs sperm transit. A classification system employed commonly in clinical practice, and the basis for which

this document is organized, distinguishes between obstructive azoospermia (OA) and nonobstructive azoospermia (NOA). NOA can be further divided into central NOA and testicular NOA. Generally, men with azoospermia, normal size testes, and normal serum follicle-stimulating hormone (FSH) levels have normal spermatogenesis and are more likely to have OA, while men with a significant elevation in FSH have testicular failure, and thus testicular NOA. Low levels of gonadotropins and low or low-normal testosterone (T) suggest a central NOA diagnosis. The etiological diagnosis is made based upon a detailed clinical history, physical exam, and endocrine evaluation, in addition to supplemental testing.

INITIAL EVALUATION OF THE AZOOSPERMIC MALE

A standard reproductive history and physical exam should be performed as per the American Society for Reproductive Medicine (ASRM) Practice Committee report “Diagnostic evaluation of the infertile male: a committee opinion” [3]. Hormonal abnormalities of the hypothalamic-pituitary-gonadal axis are well recognized causes of male infertility and represent a

necessary component of the evaluation of the azoospermic male. For azoospermic men, the minimum initial hormonal evaluation should include measurement of serum FSH and total T concentrations, although most cases will require complete hormone testing, including luteinizing hormone (LH), free T, estradiol, and prolactin. Whereas some men with abnormal spermatogenesis may have a serum FSH level within normal limits, an elevated serum FSH concentration indicates an abnormality in spermatogenesis. While various labs have different reference ranges, most experts state that an FSH >7.6 mIU/mL would be considered abnormal [3].

OBSTRUCTIVE AZOOSPERMIA

In men with low ejaculate volume (<1.5 mL) and normal FSH and testis volume, determinations of collection error and a post-ejaculate urinalysis (PEU) to evaluate possible retrograde ejaculation are important first steps. A significant amount of retrograde ejaculation generally demonstrates millions of sperm on the PEU. When men with low ejaculate volume and palpable vasa do not have retrograde ejaculation and semen pH is less than 7.2, a transrectal ultrasound (TRUS) to evaluate dilation of seminal vesicles or ejaculatory ducts is a useful diagnostic test to identify ejaculatory duct obstruction (EDO) (Fig. 1) [4].

Received January 24, 2018; accepted January 25, 2018.

Reprint requests: Practice Committee, American Society for Reproductive Medicine, 1209 Montgomery Hwy, Birmingham, Alabama 35216 (E-mail: ASRM@asrm.org).

Fertility and Sterility® Vol. 109, No. 5, May 2018 0015-0282/\$36.00

Copyright ©2018 American Society for Reproductive Medicine, Published by Elsevier Inc.

<https://doi.org/10.1016/j.fertnstert.2018.01.043>

TABLE 1

Classification scheme of azoospermia based upon pre-testicular, testicular, and post-testicular etiologies.

Etiology	Semen volume	T	FSH
Pre-testicular			
Hypogonadotropic hypogonadism	N / ↓	↓	↓
Exogenous androgens	N / ↓	↑ / N / ↓	↓
Testicular			
Primary testicular failure, genetic etiology, varicocele	N	↓	↑
Post-testicular			
Vasectomy, epididymal obstruction	N	N	N
Ejaculatory duct obstruction, ejaculatory dysfunction	↓	N	N / ↑

FSH = follicle-stimulating hormone, N = normal, T = testosterone.

ASRM. Evaluation of the azoospermic male. *Fertil Steril* 2018.

AZOOSPERMIC MEN WITH LOW EJACULATE VOLUME

In the absence of vasal agenesis or testicular atrophy, semen volume and serum FSH are key factors in determining the etiology of azoospermia. Men with low ejaculate volume should have the semen analysis repeated, with attention paid toward complete and proper collection after allowing 2–3 days abstinence (5). Low ejaculate volume not related to hypogonadism or congenital bilateral absence of the vas deferens (CBAVD) can be caused by ejaculatory dysfunction, but the most likely etiology is EDO.

Additional seminal parameters that can help to identify EDO are acidic seminal pH (<7.2) and absent fructose, because seminal vesicle secretions are alkaline and contain fructose. However, semen pH and fructose testing may be misleading when not properly performed, leading many experts to rely on other clinical findings. TRUS is indicated in men with low ejaculate volume and palpable vasa to identify potential causes of EDO such as midline cysts, dilated ejaculatory ducts, and/or dilated seminal vesicles (>1.5 cm in diameter). These findings suggest, but do not establish, the diagnosis of EDO. Conversely, normal seminal vesicle size does not exclude entirely the possibility of obstruction (6). Approximately 10%–15% of CBAVD have unilateral renal agenesis not associated with a cystic fibrosis transmembrane conductance regulator (CFTR) mutation. This may be explained by a different genetic mutation that leads to anomalies in the Wolffian duct with subsequent abnormalities in the seminal vesicles, vas deferens, and epididymis (7). Unilateral renal agenesis (URA) is a relatively common congenital condition that may be caused by a problem with formation of the entire Wolffian duct, ureteral bud maldevelopment, or degeneration of the ureteral bud at an early stage (8). The established embryological development coupled with the absence of CFTR mutation in this smaller subset of patients may suggest that the genetic basis is a variant in expression of an abnormality in a gene, or genes, required for nephrogenesis.

AZOOSPERMIC MEN WITH NORMAL EJACULATE VOLUME

In azoospermic men with normal semen volume, the serum FSH and testicular volume are the most important factors for determining whether a diagnostic testicular biopsy may be helpful to assess spermatogenesis (9). Marked elevation of serum FSH and low testicular volume strongly suggests NOA (3). When sperm retrieval for intracytoplasmic sperm injection (ICSI) is considered, a diagnostic testicular biopsy for prognostic purposes alone is typically deferred in lieu of a formal sperm retrieval during which time a biopsy may additionally be sent for pathologic analysis.

A normal testicular biopsy or aspirate implies obstruction at some level in the reproductive system, and the location must then be determined. Most men with OA that cannot be attributed to iatrogenic vasal injury (e.g., prior scrotal, inguinal, pelvic surgery or trauma) or CBAVD have bilateral epididymal obstruction, which can be confirmed only by surgical exploration. Vasography may help to identify obstruction in the vas deferens or ejaculatory ducts. However, due to the risk of vasal scarring and obstruction, vasography should not be performed at the time of diagnostic testicular biopsy unless reconstructive surgery is performed simultaneously. Additionally, reconstruction in the setting of likely epididymal obstruction should be coupled with sperm retrieval and cryopreservation in case assisted reproduction becomes necessary in the future.

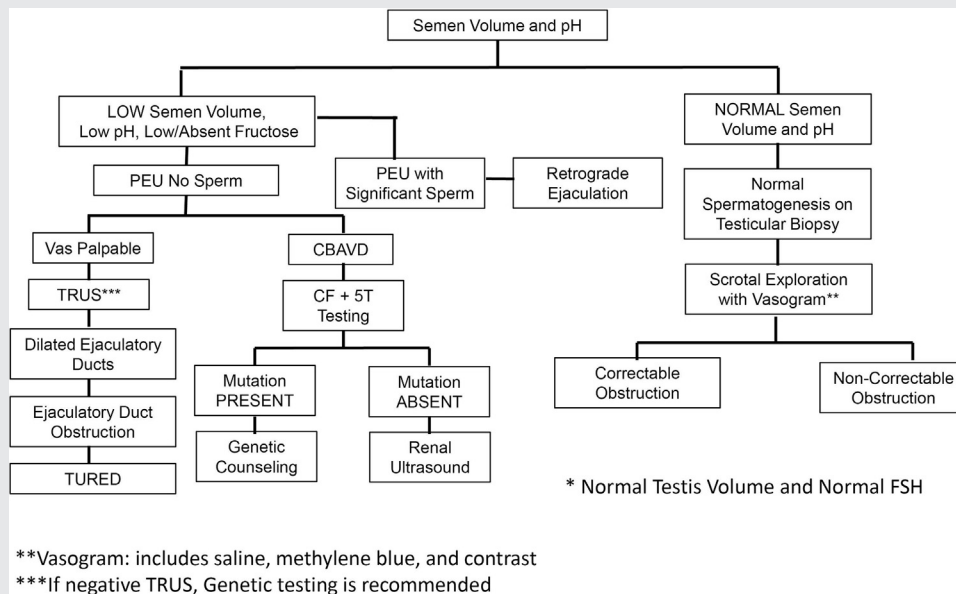
Some men with normal-volume azoospermia will have a normal testicular exam, normal FSH, and a testicular biopsy that demonstrates a spermatogenesis defect (most often maturation arrest). These men have NOA and should not be offered scrotal exploration and reconstruction.

CONGENITAL BILATERAL ABSENCE OF THE VASA DEFERENTIA (VASAL AGENESIS)

Because normal vasa can be palpated easily within the scrotum, the diagnosis of unilateral or bilateral vasal agenesis is made by physical examination. Imaging studies and surgical exploration generally are unnecessary for diagnosis but may help to identify other abnormalities associated with vasal agenesis. Approximately 25% of men with unilateral vasal agenesis and about 10%–15% with CBAVD also have unilateral renal agenesis that may be identified by ultrasonography (10). In azoospermic men with unilateral vasal agenesis, TRUS may help to demonstrate an associated contralateral segmental atresia of the vas deferens or seminal vesicle (11). Due to the embryologic association between the vasa and seminal vesicles, most men with vasal agenesis also have seminal vesicle hypoplasia or agenesis, and because the majority of the seminal fluid derives from the seminal vesicles, almost all men with CBAVD have low semen volume and pH.

There is a strong association between CBAVD and mutations of the CFTR gene (12). Almost all men with clinical cystic fibrosis have CBAVD. Conversely, at least three quarters of men with CBAVD have mutations of the CFTR gene (13). However, failure to identify a CFTR abnormality in a man with CBAVD does not exclude a mutation entirely, because 10%–40% are undetectable using common clinically

FIGURE 1



Algorithm for obstructive azoospermia.

ASRM. Evaluation of the azoospermic male. *Fertil Steril* 2018.

available methods. During comprehensive screening with CFTR gene sequencing (as opposed to the commonly used delta F508, 30-mutation, or 100-mutation panels), a small fraction of CBAVD men will have no identifiable mutations. Patients with renal anomalies and unilateral or bilateral vasal agenesis do not have rates of CFTR mutations higher than the baseline population prevalence (6, 14) and likely have a non-CFTR etiology for these anomalies. Before any treatments using sperm from a man with CBAVD or congenital unilateral absence of the vas deferens (CUAVD), testing should be offered to his female partner to exclude the possibility (~4%) that she too may be a carrier. Genetic counseling should be offered both before and after genetic testing of both partners. Most men with CBAVD have normal spermatogenesis, but other potential coexisting causes of impaired spermatogenesis should be investigated before harvesting sperm for assisted reproduction (15).

NONOBSTRUCTIVE AZOOSPERMIA

For men with suspected NOA due to an elevated FSH and a normal ejaculate volume, a diagnostic testicular biopsy is not usually indicated (Fig. 2). Men with NOA frequently have bilateral testicular atrophy, which may be caused by either primary or secondary testicular failure, though some men with maturation arrest may have normal testicular size and FSH. Low semen volume may be associated with low serum testosterone.

The results of the initial endocrine evaluation help to distinguish between primary and secondary testicular failure. An elevated serum FSH level (>7.6 mIU/mL [3]) and a normal

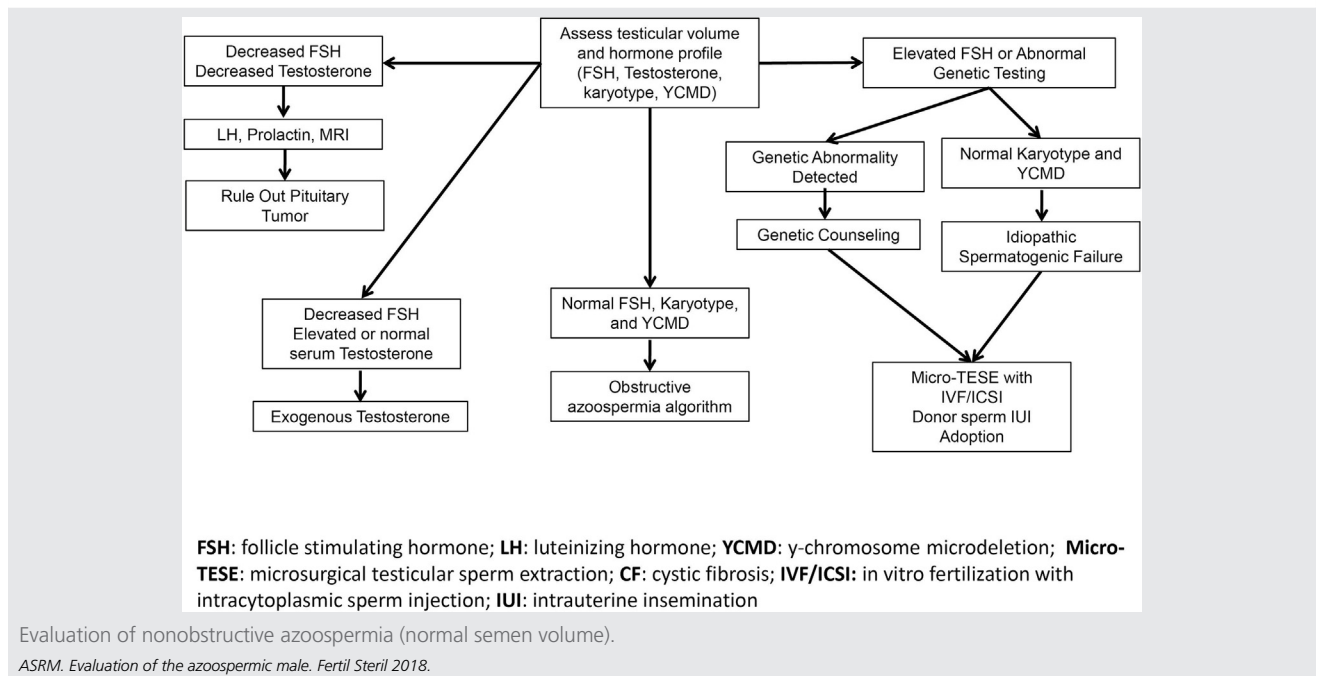
or low serum T concentration in a patient with bilateral testicular atrophy imply primary testicular failure. Men with such findings should be offered genetic testing to exclude chromosomal abnormalities and Y-chromosome microdeletions (YCMD), discussed in detail below.

Low gonadotropins and bilateral testicular atrophy suggest hypogonadotropic hypogonadism. Severe hypogonadotropic hypogonadism results from hypothalamic disorders such as Kallmann syndrome or from congenital or acquired pituitary disorders, including both functional and nonfunctional tumors, which may be associated with undetectably low gonadotropins.

Additionally, suppression of the hypothalamic-pituitary-gonadal axis with very low or undetectable gonadotropins and thus absent testicular stimulation may be due to feedback inhibition secondary to exogenous T or illicit anabolic androgenic steroid use (16); a high T level with suppressed gonadotropins is confirmatory, although a low T level coupled with low gonadotropins could be the result of recently discontinued use of exogenous androgens. Men with bilateral testicular atrophy and hypogonadotropic hypogonadism should therefore be questioned about T, anabolic androgenic steroids, and workout supplements. Regardless, azoospermic men with hypogonadotropic hypogonadism merit further evaluation, including measurement of serum prolactin and pituitary imaging.

Men with NOA and testicular atrophy associated with unilateral or bilateral varicoceles represent a unique clinical conundrum. While all of the above must be considered, including concomitant genetic etiologies, it is possible for such severe intrinsic testicular failure resulting in NOA to be the sole result of unilateral or bilateral varicoceles (17).

FIGURE 2



Varicoceles resulting in NOA are typically associated with elevated serum FSH levels. In appropriately selected individuals with NOA and varicoceles, varicocele repair may be associated with sperm returning to the ejaculate to various degrees in 10% to 40% of patients (18, 19). In addition, varicocele repair in this setting may be associated with higher sperm retrieval rates at biopsy should the patient remain azoospermic (20).

GENETIC TESTING FOR MEN WITH NONOBSTRUCTIVE AZOOSPERMIA

The causes of male infertility are often multifactorial, with approximately 50% involving genetic abnormalities. The two most common are chromosomal abnormalities resulting in impaired testicular function and YCMD resulting in isolated spermatogenic impairment.

KARYOTYPIC CHROMOSOMAL ABNORMALITIES

Chromosomal abnormalities can be identified by karyotype of peripheral leukocytes in approximately 7% of azoospermic men. Karyotype analysis detects large-scale genetic abnormalities, such as deletions of entire chromosomes or substantial portions of a chromosome, as well as translocations. The prevalence of such abnormalities relates inversely to the sperm concentration; the prevalence is 10% to 15% in azoospermic men, approximately 5% in oligospermic men, and less than 1% in men having a normal sperm concentration (21).

Sex chromosomal aneuploidy (e.g., Klinefelter syndrome) accounts for approximately two thirds of chromosomal abnormalities observed in infertile men. Men with Klinefelter syndrome are predisposed to other medical problems besides

infertility, adding importance to identifying the cause of NOA. Many of these men have low or low-normal testosterone levels. Androgen deficiency can lead to osteoporosis, decreased muscle mass, and other systemic effects including diabetes. These men also have increased risks for thromboembolic events, male breast cancer, and possibly extragonadal germ-cell cancers. Thus, referral to a genetic counselor is indicated in these patients.

The prevalence of structural abnormalities in the autosomes, such as inversions and translocations, is also higher in infertile men than in the general population. Gross karyotypic abnormalities confer an increased risk for miscarriages and/or having children with chromosomal and congenital defects (22). Similar to patients with Klinefelter syndrome, genetic counseling is important prior to ICSI/in vitro fertilization (IVF).

Y-CHROMOSOME MICRODELETIONS

The Y chromosome contains vital components needed for male differentiation and sperm function. YCMD are too small to be detected by karyotyping but can be identified using polymerase chain reaction techniques. Most YCMD occur in regions of the long arm of the Y chromosome designated as azoospermia factor (AZF)a, AZFb, or AZFc. Deletions in these locations are responsible for varying degrees of spermatogenic dysfunction and may be found in 10%–15% of men with azoospermia or severe oligospermia (23).

In men with deletions in the AZFc region, sperm can be present in the ejaculate. Others with AZFc deletions will be azoospermic, but still may have sufficient sperm production to allow sperm extraction by conventional or microsurgical testicular sperm extraction; and the results achieved with ICSI are not affected adversely (24). However, deletions

involving the AZFa or AZFb regions predict a very poor prognosis for sperm retrieval, and as such, sperm retrieval should not be attempted in these particular patients (25). Male offspring of men with AZFc deletions will inherit the abnormality and likely will be severely oligospermic or azoospermic (26). Although YCMD are not known to be associated with other health problems, data regarding the phenotypes of sons of men with such abnormalities are still quite limited (26).

Genetic counseling should be offered whenever a genetic abnormality is suspected, in either the male or female partner, and should be provided whenever a genetic abnormality is detected. Therefore, men with NOA should be offered karyotyping and YCMD analysis, as well as receive genetic counseling if necessary, before their sperm are used for ICSI.

INDICATIONS FOR TESTICULAR BIOPSY

When sperm retrieval for ICSI is considered, a diagnostic testicular biopsy for prognostic purposes alone is typically deferred in lieu of a formal sperm retrieval by a male reproductive expert, during which time a biopsy may additionally be sent for pathologic analysis if necessary. There is limited utility of diagnostic biopsy in men with markedly elevated serum FSH levels; in certain circumstances, however, a diagnostic biopsy may still be of value.

Diagnostic testicular biopsy or aspiration is primarily indicated if there is uncertainty whether the patient has obstructive or nonobstructive azoospermia. An example is an azoospermic patient with normal semen volume, normal or near normal testicular volume, at least one palpable vasa, and a normal or near-normal serum FSH concentration (which does not always guarantee normal spermatogenesis). If possible, the biopsy or aspirate is performed with the additional ability to examine the tissue for sperm and to cryopreserve it, potentially avoiding the need for a second procedure; when doing so, the biopsy or aspirate is then called a testicular sperm extraction (TESE) or testicular sperm aspiration (TESA).

In an azoospermic patient with expected obstruction (e.g. prior vasectomy, bilateral inguinal hernia surgery) associated with a normal serum FSH level, a diagnostic biopsy is not necessary. Surgical reconstruction with or without formal sperm retrieval should be considered in such cases. For a patient expected to have NOA based on clinical data (e.g., testicular atrophy with elevated FSH level), a diagnostic testicular biopsy should not be performed.

SUMMARY

- The diagnosis of azoospermia is established when no sperm are detected in at least two separate centrifuged semen samples.
- Azoospermia may be either due to obstruction or spermatogenic failure (nonobstructive).
- Genetic mutations are important causes of azoospermia.

CONCLUSIONS

- The minimum initial evaluation of azoospermic men should include a complete medical history, physical exam-

ination, and measurements of serum total T and FSH, as well as appropriate genetic testing.

- Men with NOA (not due to hypogonadotropic hypogonadism) should be offered genetic testing to exclude chromosomal abnormalities and YCMD.
- Azoospermic men with hypogonadotropic hypogonadism should be queried for exogenous androgen use and evaluated by measurement of serum prolactin and pituitary imaging to exclude pituitary pathology.
- A man with CBAVD should be assumed to harbor a CFTR mutation (unless there is renal agenesis/anomalies) and testing should be offered to the female partner. These couples should also be offered genetics counseling, even if the female partner tests negative.
- In azoospermic men with low ejaculate volume and palpable vasa, testicular biopsy or aspirate may be performed to confirm the presence of obstruction. TRUS, with or without SVA, may be used to identify EDO.

Acknowledgements: This report was developed under the direction of the Practice Committee of the American Society for Reproductive Medicine as a service to its members and other practicing clinicians. Although this document reflects appropriate management of a problem encountered in the practice of reproductive medicine, it is not intended to be the only approved standard of practice or to dictate an exclusive course of treatment. Other plans of management may be appropriate, taking into account the needs of the individual patient, available resources, and institutional or clinical practice limitations. The Practice Committee and the Board of Directors of the American Society for Reproductive Medicine have approved this report.

This document was reviewed by ASRM members and their input was considered in the preparation of the final document. The Practice Committee acknowledges the special contribution of Kathleen Hwang, M.D., James F. Smith, M.D., M.S., and R. Matthew Coward, M.D. in the preparation of this document. The following members of the ASRM Practice Committee participated in the development of this document. All Committee members disclosed commercial and financial relationships with manufacturers or distributors of goods or services used to treat patients. Members of the Committee who were found to have conflicts of interest based on the relationships disclosed did not participate in the discussion or development of this document.

Alan Penzias, M.D.; Kristin Bendikson, M.D.; Samantha Butts, M.D., M.S.C.E.; Christos Coutifaris, M.D., Ph.D.; Tommaso Falcone, M.D.; Gregory Fossum, M.D.; Susan Gitlin, Ph.D.; Clarisa Gracia, M.D., M.S.C.E.; Karl Hansen, M.D., Ph.D.; Sangita Jindal, Ph.D.; Andrew La Barbera, Ph.D.; Jennifer Mersereau, M.D.; Randall Odem, M.D.; Richard Paulson, M.D.; Samantha Pfeifer, M.D.; Margareta Pisarska, M.D.; Robert Rebar, M.D.; Richard Reindollar, M.D.; Mitchell Rosen, M.D.; Jay Sandlow, M.D.; Dale Stovall, M.D.; Michael Vernon, Ph.D.

REFERENCES

1. Stephen EH, Chandra A. Declining estimates of infertility in the United States: 1982-2002. *Fertil Steril* 2006;86(3):516-23.

2. Jarow JP, Espeland MA, Lipshultz LI. Evaluation of the azoospermic patient. *J Urol* 1989;142(1):62–5.
3. Practice Committee of the American Society for Reproductive. Diagnostic evaluation of the infertile male: a committee opinion. *Fertil Steril* 2015;103(3):e18–25.
4. Roberts M, Jarvik. Steps in the investigation and management of low semen volume in the infertile man. *Can Urol Assoc J* 2009;3(6):479–85.
5. Paick J, Kim SH, Kim SW. Ejaculatory duct obstruction in infertile men. *BJU Int* 2000;85(6):720–4.
6. McCallum T, Milunsky J, Munarriz R, Carson R, Sadeghi-Nejad H, Oates R. Unilateral renal agenesis associated with congenital bilateral absence of the vas deferens: phenotypic findings and genetic considerations. *Hum Reprod* 2001;16(2):282–8.
7. Mesrobian HG, Rushton HG, Bulas D. Unilateral renal agenesis may result from in utero regression of multicystic renal dysplasia. *J Urol* 1993;150:793–4.
8. Coburn M, Wheeler T, Lipshultz LI. Testicular biopsy. Its use and limitations. *Urol Clin North Am* 1987;14(3):551–61.
9. Schoor RA, Elhanbly S, Niederberger CS, Ross LS. The role of testicular biopsy in the modern management of male infertility. *J Urol* 2002;167(1):197–200.
10. Schlegel PN, Shin D, Goldstein M. Urogenital anomalies in men with congenital absence of the vas deferens. *J Urol* 1996;155(5):1644–8.
11. Hall S, Oates RD. Unilateral absence of the scrotal vas deferens associated with contralateral mesonephric duct anomalies resulting in infertility: laboratory, physical and radiographic findings, and therapeutic alternatives. *J Urol* 1983;50(4):1161–4.
12. Chillon M, Casals T, Mercier B, Bassas L, Lissens W, Silber S, et al. Mutations in the cystic fibrosis gene in patients with congenital absence of the vas deferens. *N Engl J Med* 1995;332(22):1475–80.
13. Yu J, Chen Z, Ni Y, Li Z. CFTR mutations in men with congenital bilateral absence of the vas deferens (CBAVD): a systemic review and meta-analysis. *Hum Reprod* 2012;27(1):25–35.
14. Schwarzer JU, Schwarz M. Significance of CFTR gene mutations in patients with congenital aplasia of vas deferens with special regard to renal aplasia. *Andrologia* 2012;44(5):305–7.
15. Meng MV, Black LD, Cha I, Ljung BM, Pera RA, Turek PJ. Impaired spermatogenesis in men with congenital absence of the vas deferens. *Hum Reprod* 2001;16(3):529–33.
16. Kolettis PN, Purcell ML, Parker W, Poston T, Nangia AK. Medical testosterone: an iatrogenic cause of male infertility and a growing problem. *Urology* 2015;85(5):1068–72.
17. Shiraishi K, Oka S, Matsuyama H. Predictive factors for sperm recovery after varicocelectomy in men with NOA. *J Urol* 2017;197(2):485–90.
18. Esteves SC, Miyaoka R, Roque M, Agarwal A. Outcome of varicocele repair in men with nonobstructive azoospermia: systematic review and meta-analysis. *Asian J Androl* 2016;18(2):246–53.
19. Schlegel PN, Kaufmann J. Role of varicocelectomy in men with nonobstructive azoospermia. *Fertil Steril* 2004;81(6):1585–8.
20. Inci K, Hascicek M, Kara O, Dikmen AV, Gurgan T, Ergen A. Sperm retrieval and intracytoplasmic sperm injection in men with nonobstructive azoospermia, and treated and untreated varicocele. *J Urol* 2009;182(4):1500–5.
21. Samli H, Samli MM, Solak M, Imirzalioglu N. Genetic anomalies detected in patients with non-obstructive azoospermia and oligozoospermia. *Arch Androl* 2006;52(4):263–7.
22. Foresta C, Ferlin A, Gianaroli L, Dallapiccola B. Guidelines for the appropriate use of genetic tests in infertile couples. *Eur J Hum Genet* 2002;10(5):303–12.
23. Pryor JL, Kent-First M, Muallem A, Van Bergen AH, Nolten WE, Meisner L, Roberts KP. Microdeletions in the Y chromosome of infertile men. *N Engl J Med* 1997;336(8):534–9.
24. Oates RD, Silber S, Brown LG, Page DC. Clinical characterization of 42 oligospermic or azoospermic men with microdeletion of the AZFc region of the Y chromosome, and of 18 children conceived via ICSI. *Hum Reprod* 2002;17(11):2813–24.
25. Hopps CV, Mielnik A, Goldstein M, Palermo GD, Rosenwaks Z, Schlegel PN. Detection of sperm in men with Y chromosome microdeletions of the AZFa, AZFb and AZFc regions. *Hum Reprod* 2003;18(8):1660–5.
26. Lee SH, Ahn SY, Lee KW, Kwack K, Jun HS, Cha KY. Intracytoplasmic sperm injection may lead to vertical transmission, expansion, and de novo occurrence of Y-chromosome microdeletions in male fetuses. *Fertil Steril* 2006;85:1512–5.